

CASE STUDY

Management of Adenocarcinoma in the Right Mainstem and Bronchus Intermedius with the Use of Multiple AEROmini[®] Through-the-Scope Stents.

Dr. Deepankar Sharma

Director of Interventional Pulmonology
Columbus Regional Health, Columbus, IN

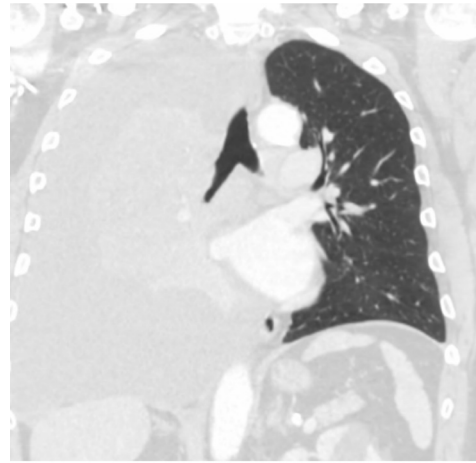
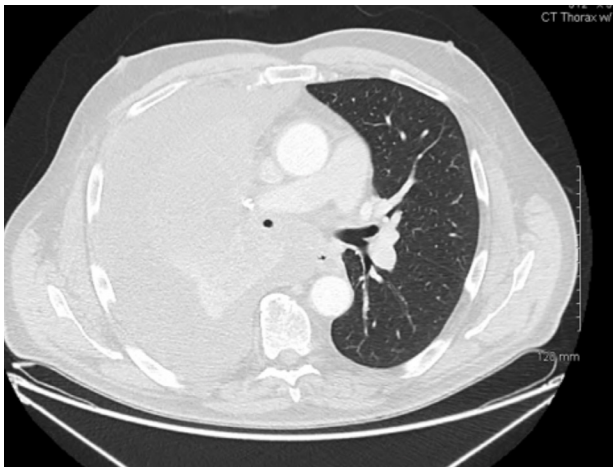

PRESENTATION

A 68-year-old man with known adenocarcinoma of the rectum, failed to complete a recommended treatment in the past, presented with gradual worsening of shortness of breath.

WORK UP

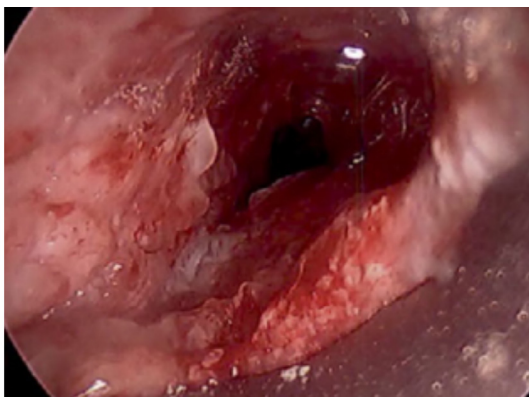
A CT chest scan revealed a large pleural effusion and complete stenosis of the right upper lobe, bronchus intermedius, and narrowing of the right mainstem bronchus.



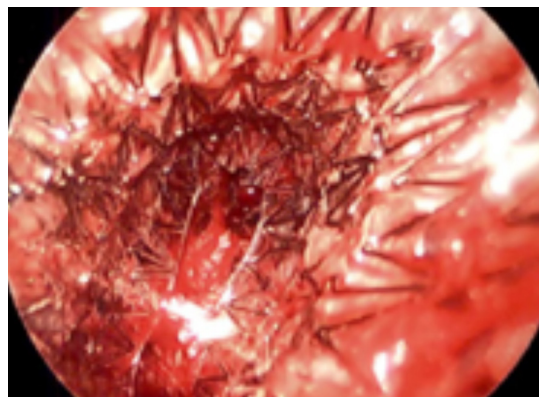
INTERVENTION

Rigid bronchoscopy revealed 100% occlusion of right upper lobe beyond salvage, and tumor invasion causing severe narrowing of right lower lobe, bronchus intermedius and right mainstem bronchus. Nd:YAG laser was used to treat the mucosal infiltration of tumor followed by AERO[®] Tracheobronchial stents placed in the right lower lobe and bronchus intermedius.

Right Lower Lobe Endobronchial Tumor

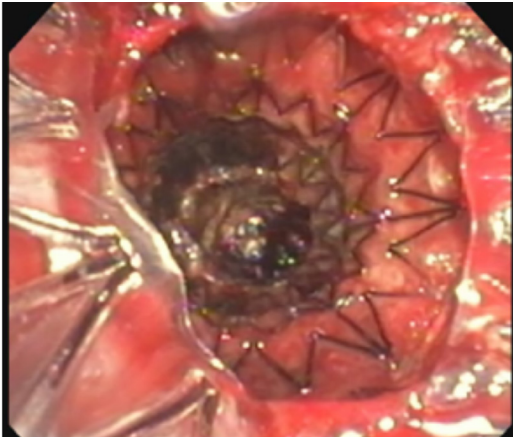


Right Lower Lobe Stent

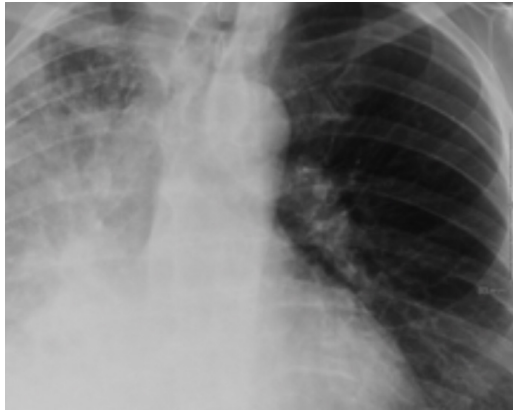
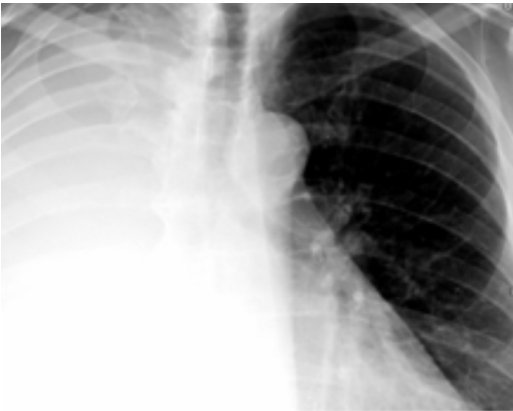
CONTINUED

Distal Edge of Bronchus Intermedius and Proximal Edge of Right Lower Lobe Stent



Pre and Post Op CXR



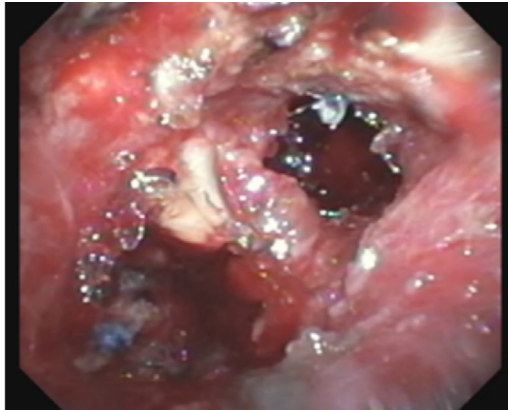
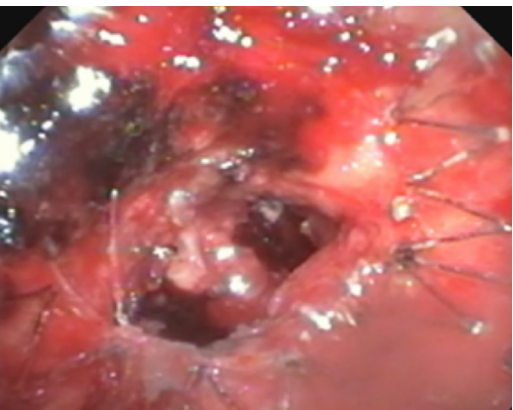
FOLLOW UP

Biopsy confirmed metastatic rectal adenocarcinoma. The patient started treatment with Oxaliplatin and Xeloda. He did well for about seven months, then developed worsening respiratory symptoms with a right lower lobe collapse.

REPEAT INTERVENTION

A second rigid bronchoscopy was done which revealed worsening endobronchial tumor distal to the existing right lower lobe stent. Tumor debulking and ablation was performed using endobronchial rigid forceps and Argon Plasma Coagulation. Additional balloon dilation was performed, followed by the placement of two 6mm x 10mm AEROMini® Through-the-Scope stents in viable basilar segments of right lower lobe.

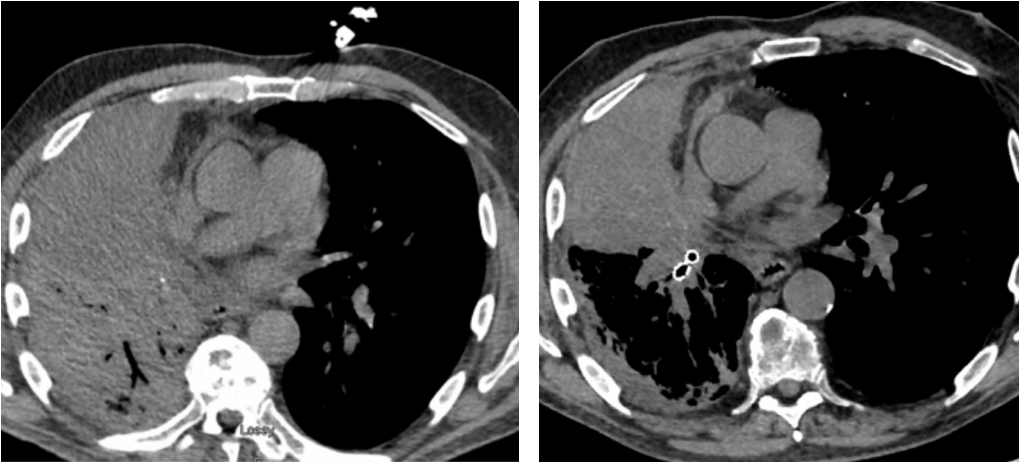
Right Lower Lobe Basal Segment AEROMini Stents Distal to Stent



FOLLOW UP


The patient has been on XELIRI and Avastin® and has been doing well without any deterioration in his functional status. Follow-up imaging continues to appear stable without any new or worsening right lung collapse.

CT Chest Pre and Post Right Lower Lobe Basilar Segment AEROMini Stents



CONCLUSION

The use of the fully covered AEROMini® Tracheobronchial Stent System can be a successful therapy option for the management of stenosis in the lower airways.



The above information, which may include both Merit and third-party products, are for the practitioner's convenience and for general information purposes only. This information does not constitute medical or legal advice, nor is it meant to endorse or guarantee the suitability of any of the referenced products or methods for any specific patient or procedure. Before using any product, refer to the Instructions for Use (IFU) for indications, contraindications, warnings, precautions, and directions for use.