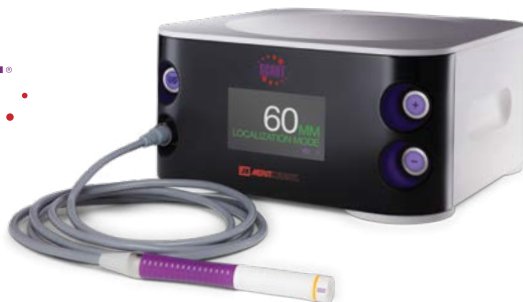



Reducing the Localization Regulatory Burden

Roshni Rao, MD

Chief, Division of Breast Surgery
Vivian L. Milstein Associate Professor of Surgery
Columbia University/New York Presbyterian

Patient: 66-year-old female

Diagnosis: Left breast ductal carcinoma DCIS

Rx: Removal of SCOUT and DCIS

Challenge: Patients who undergo radioactive seed localization (RSL) then elect to continue their care at a different institution that does not perform RSL

Patient History

66 yo female who underwent screening mammogram and was identified to have new suspicious calcifications in the lower outer quadrant, 5.5 cm from the nipple, that were spanning 1.2 cm. Stereotactic biopsy with clip placement was performed and revealed DCIS associated with radial scar and atypical ductal hyperplasia (Figure 1). Post procedure mammogram revealed the clip was displaced from the biopsy site, but residual calcifications could be seen. Tumor was ER/PR positive. Ultrasound revealed no evidence of additional lesions of concern nor axillary lymphadenopathy. Options for treatment were discussed with this patient, and she sought several opinions given that she lived in a very large metropolitan area. Patient is a known diabetic with a prior history of vascular disease managed by bypass in the past.

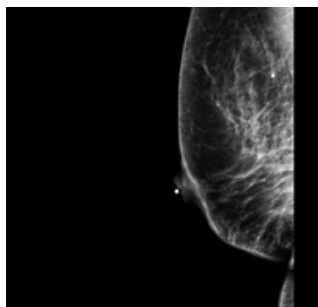


Figure 1

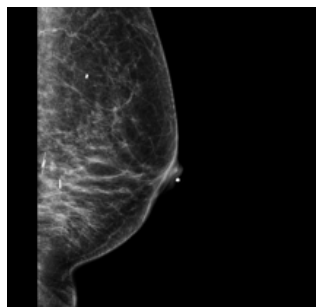


Figure 2

Initial radioactive seed localization (RSL)

The patient elected to undergo breast conservation and opted for surgery at a different hospital. Three days prior to surgery, she underwent radioactive seed localization (RSL) at that hospital. Her surgery was cancelled due to high blood glucose levels and she was re-scheduled. Subsequently, the patient opted to transfer her care back to our institution given her comfort with the medical team there.

Surgery

The patient was scheduled for surgery at our institution but did not reveal that she had undergone prior RSL. She was therefore scheduled for and underwent SCOUT localization as this is the standard practice at our institution. During the localization, the breast radiologist became suspicious and recognized the additional marker as a radioactive seed (Figure 2).

After discussion, which included the possibility of sending the patient back to the hospital that placed the seed, it was decided to perform a partial mastectomy with the SCOUT in place and with two breast surgeons, one of whom had extensive experience with radioactive seeds from a previous institution. This plan was formulated with radiation safety officers from both institutions.

The surgery proceeded without complications, guided by both the SCOUT guide and the Neoprobe set for I-125. Specimen radiograph revealed retrieval of both the seed and the SCOUT Reflector (Figure 3). The radioactive seed was removed from the specimen in the OR, placed into a lead container, and transferred to the radiation safety officer in the operating room.

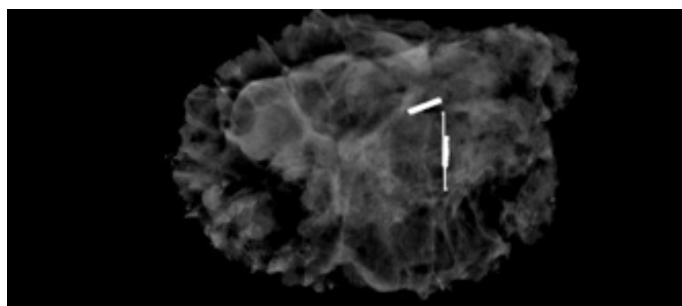


Figure 3

Pathology

Final pathology revealed 5 mm of DCIS with all margins >2 mm. The radioactive seed was sent back to the hospital that had originally placed it via their radiation safety officer.

Conclusion

The regulatory burden of RSL can be tremendous. Even in experienced centers, mishaps such as this can occur. If the radioactive seed had not been recognized as such by the radiologist, which allowed all appropriate precautions to be taken by the team, there could be a risk of seed perforation during the operation, which results in significant radiation exposure. It was serendipitous that this patient was managed at our institution, with staff who had prior experience with RSL. SCOUT localization is not associated with these radioactivity or regulatory burdens, and is cleared for long-term placement which minimizes patient safety concerns and provides flexibility for SCOUT localization for patients undergoing neoadjuvant chemotherapy prior to surgical management.



ciannamedical.com/savi-scout
merit.com

The foregoing case and other information are for the practitioner's convenience and for general information purposes only. This information does not constitute medical or legal advice, nor is it meant to endorse or guarantee the suitability of any of the referenced products or methods for any specific patient or procedure. Before using any product, refer to the Instructions for Use (IFU) for indications, contraindications, warnings, precautions, and directions for use.